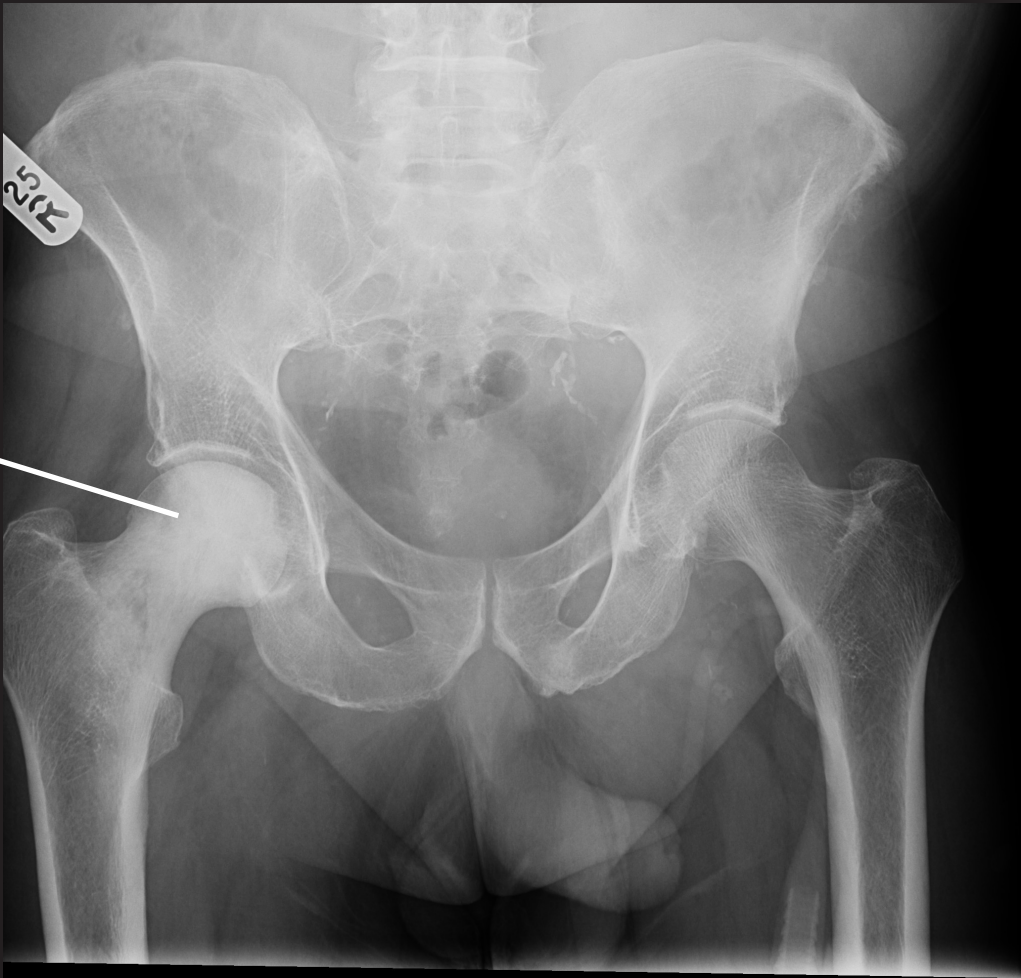
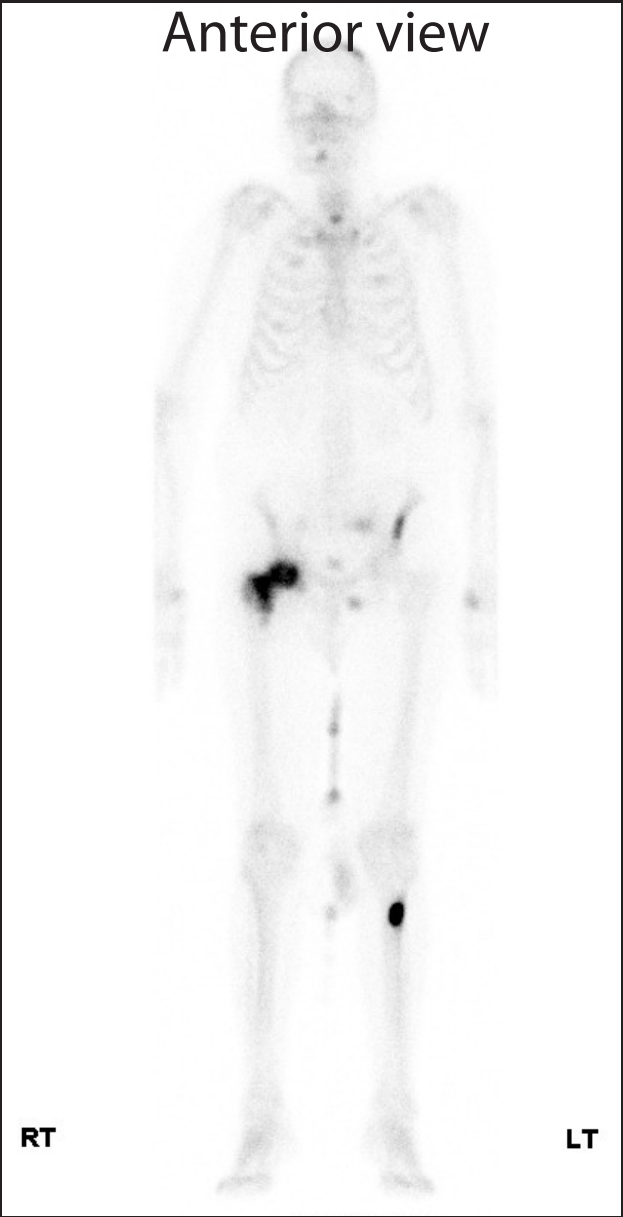

Images of a 73 year old man presenting with right hip pain. The sclerotic metastasis in the right femoral head on plain x-ray is characteristic of secondaries from prostate cancer. The bone scan demonstrates additional metastases to be scattered throughout the skeleton (dark areas).

Pelvic X-ray showing sclerotic metastasis in right femoral head



Anterior view



Posterior view

